

# Failed Pilonidal Surgery

## *New Paradigm and New Operation Leading to Cures*

John Bascom, MD, PhD; Thomas Bascom, MD

**Hypothesis:** Refractory pilonidal disease is due to damage of the epidermis in the deep gluteal cleft by moisture and bacteria, rather than to damage in deep tissues. A new paradigm suggests that a procedure to change the shape of the gluteal cleft will improve results.

**Design:** Before-and-after trial.

**Setting:** Community private practice with extensive experience in pilonidal disease, providing ambulatory and hospital care.

**Patients:** Thirty-one patients with severe refractory pilonidal disease, with a median follow-up of 20 months in 27 patients (87%). Patients had undergone a total of 141 operations with wounds still open for a combined total of 252 years.

**Intervention:** The deep gluteal cleft was reshaped with a skin flap. Deep tissue was left essentially intact.

**Main Outcome Measures:** Number healed, time to healing, number of operations required.

**Results:** Wounds in all 31 patients healed, 28 after a single procedure. The time to healing was rapid, within 1 week in 22 patients. There were no recurrences.

**Conclusions:** For refractory pilonidal disease, the cleft lift procedure produced rapid results by drawing intact skin over the cleft and bringing the suture line out to open air. The failures of old methods and success of this new one suggest a need for a paradigm shift in our understanding of pilonidal disease. The source of disease is not the deep tissue but rather the epidermis in the moist, hypoxic, and bacteria-laden gluteal cleft. This also has implications for initial treatment of pilonidal disease, where simple, nonoperative treatments are often effective.

*Arch Surg.* 2002;137:1146-1150

**I**N AN INVITED editorial response to an earlier article on pilonidal disease by one of us (J.B.), an English surgeon wrote,

There comes a time in the treatment of surgical disease when conventional methods are no longer improving the outlook for the patients and a paradigm shift in our concepts of aetiology and hence surgical treatment is required. The author has given us this opportunity by not only challenging convention but also providing us with a lucid alternative thesis and compelling arguments for changing current surgical practice.<sup>1</sup>

This article aims to reinforce this shift by reporting on successful treatment of complicated pilonidal disease.

A paradigm shift had been building in pilonidal disease for 60 years or more. During World War II, the Surgeon General forbade wide excision as treatment for pilonidal disease because it hospitalized 79 000 troops for an average of 55 days. Much sci-

entific evidence has accumulated on the topic, but no satisfactory general theory of origin has explained the findings.

### *See Invited Critique at end of article*

In its initial presentation, pilonidal disease often responds to conventional treatment. However, sometimes despite (or because of) surgical procedures, wounds break down, fistulas develop, and wounds remain open despite multiple operations and years of care and effort. Pilonidal disease then lives up to its reputation as a condition that frustrates surgeon and patient alike. The goal of this article is to assist surgeons in shifting to the new paradigm for pilonidal disease, first by proposing better explanations for the origin of unhealed wounds and second by describing a simplified operation that brings the most difficult of unhealed pilonidal wounds under prompt control.

*Drs J. Bascom and T. Bascom  
are in private practice in  
Eugene, Ore.*

Strong evidence shows that pilonidal disease originates in the epidermis in a midline stretched hair follicle.<sup>2</sup> This follicle is the “pore” or “pit” of origin and is analogous to an epidermal inclusion microcyst. Early pilonidal changes are amplified by further epidermal and deep tissue disruption from moisture, anaerobic conditions, hair, and bacteria. Moisture creates an environment that is friendly to anaerobic bacteria and results in maceration of epidermis and loss of this natural barrier to infection. Marks et al<sup>3</sup> showed that length of pilonidal healing delay correlates with the number of anaerobic colonies present. Although hypoxia of cavity contents has not been proved in unhealed pilonidal wounds, the presence of anaerobes is strong evidence of local lack of ambient oxygen. The role of hypoxia in wounds is well studied: Hunt et al<sup>4</sup> stated that unremitting hypoxia slows collagen accumulation in wounds, and Allen et al<sup>5</sup> showed that hypoxia limits bacterial killing. However, it is not clear whether ambient hypoxia stalls healing directly or acts indirectly by encouraging growth of anaerobes, the products of which interfere with healing.

Although deep tissue hypoxia has been suggested as a cause, further evidence shows that deep tissue processes are not to blame for ongoing pilonidal disease: Karydakos<sup>6</sup> and Kitchen<sup>7</sup> moved suture lines toward open air and complex wounds healed. Others left all deep tissues in place and brushed out debris, and pilonidal wounds healed.<sup>8-10</sup> As for fistulas, the old paradigm regards fistulous tracts as primary disease that must be removed. In fact, as with other deep tissue disease, fistulas can be scrubbed clean and left in place and will heal once the midline source is controlled.<sup>11</sup>

Fistulas develop as extensions of chronic pilonidal abscesses when hair, debris, and air are sucked into an abscess cavity by a subcutaneous vacuum<sup>12</sup> that forms during repeated standing and sitting. In standing, the patient's bones lift away first, pulling away from soft tissues, creating a vacuum. In sitting, the pilonidal opening is pushed closed and the cavity is compressed, creating pressure that drives contents through fat to eventually rupture through buttock skin as secondary openings.

On the basis of these observations, a new paradigm or theory of origin emerges that pilonidal disease is exclusively an epidermal problem, rather than a deep tissue problem, which is the theory behind current recommendations for wide excision.<sup>13-17</sup> Pilonidal wounds remain open if conditions in the gluteal cleft are unchanged. Therefore, the focus of treatment should be actions to change the conditions that attack epidermis, rather than wide excision, which attacks deep and healable tissue. Although this paradigm shift may seem radical, it warrants adoption because treatment of these patients based on its precepts resulted in healing of even the most refractory cases.

## PATIENTS AND METHODS

### PATIENTS

Thirty-one patients were referred for care after repeated failure of previous pilonidal surgeries. All 31 patients had persis-

tent open wounds and had undergone at least 2 pilonidal operations. They were part of a consecutive series of 623 patients treated for pilonidal disease in a community, private, general surgery practice. Some were included in earlier reports.<sup>18</sup> Pilonidal disease first appeared in all patients during their teens or early 20s. Men and women were about equally represented. By chart review of the history and of our findings at examination and surgery, we identified the probable causes of previous failure to heal. Time to healing was recorded, as were persistent symptoms, number of operations required, and recurrences.

### CLEFT LIFT OPERATIVE TECHNIQUE

We devised a relatively simple operation to address unhealed pilonidal wounds, which have often been exacerbated by previous overintensive surgery. This procedure, which we have termed *cleft lift*, is our modification of the successful method of Karydakos<sup>6</sup> and Kitchen.<sup>7</sup> More detailed description of the procedure has been published previously.<sup>18,19</sup>

The operation proceeds as follows. An ellipse of skin is removed from the left wall of the gluteal cleft. Skin from the right wall is raised to drape loosely across the midline. A new suture line is laid parallel to the midline, but to one side of it, nearer to open air. Intact skin now shapes a shallower midline.

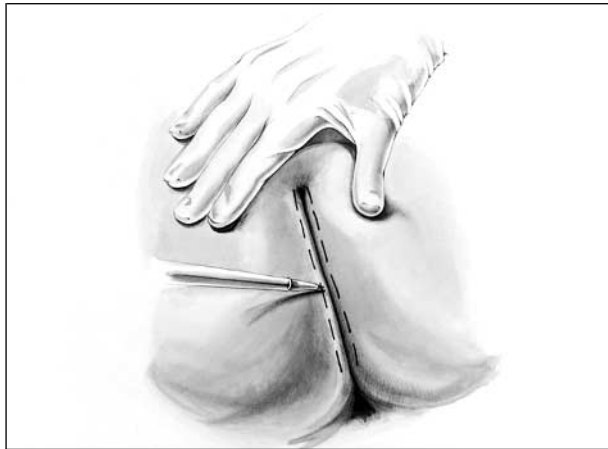For the operation to be successful, the surgeon must plot carefully the skin to be removed, ie, the ellipse from the left wall. The buttocks are pushed together before surgery and the normal outer line of contact is marked (**Figure 1**). Starting and ending points of the final suture line are marked with dots, clear and durable, 2 cm beyond each end of all midline defects but 2 cm to the left. An ellipse 4 cm wide is drawn between the dots, tapered to a sharp point at each dot. The dimensions of the ellipse are adjusted to fit the patient. This ellipse will be discarded (**Figure 2**, red line).

Next, an oval zone of the skin is outlined to be undermined and released from deeper tissues (**Figure 2**, blue line). The incisions are begun on the right or midline side of the ellipse. The knife goes 1 mm to the right of the unhealed defect. This saves the maximum possible skin for a right flap to cover the left excision. Skin 7 mm thick is freed from the right and left walls of the cleft (**Figure 3**). This unroofs the chronic abscess cavity, which is scrubbed clean with gauze. Secondary openings are enlarged to improve drainage; fistulas between secondary openings and the cavity are cleaned by pulling a sponge through them. There is no need to excise or close fistulous tracts; they will heal by secondary intention.


Recurrent or persistent fistula should prompt closer evaluation for an overlooked persistent midline defect in the epidermis. In rare cases, epidermis will have grown down the wall of a fistula; this is readily apparent by gross examination and, although exceedingly rare, is the one circumstance in which the fistula should be excised.

Before the irrevocable move of cutting along the left side to remove the ellipse, the fit should be checked to avoid a closure that is too tight or too loose. (Rarely, a deep scar formed from a contracted fibrous abscess will restrict the falling together of soft fat. Under these circumstances, we recommend shaving off the deep scar tissues.) The tapes are released and the buttocks pushed together into normal position, and then the right flap is pulled across (**Figure 4**).

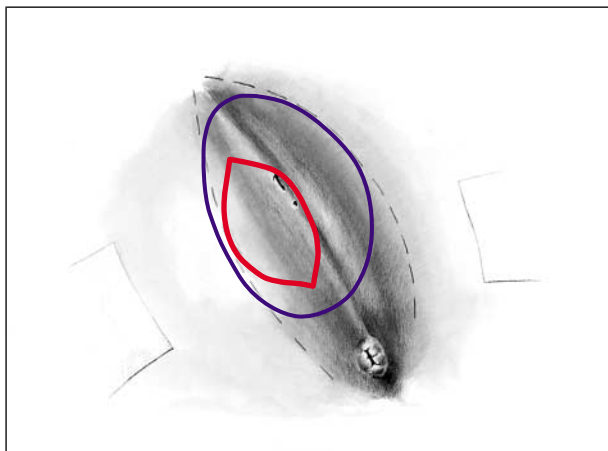
The cleft can be obliterated above the tip of the sacrum, but a midline sag should be left below the tip of the sacrum to give comfort with sitting. With the ellipse removed, the fat is approximated with light sutures and the skin is closed with removable subcuticular polypropylene sutures. Tapes reinforce the suture line (**Figure 5**). (For those interested in the tech-



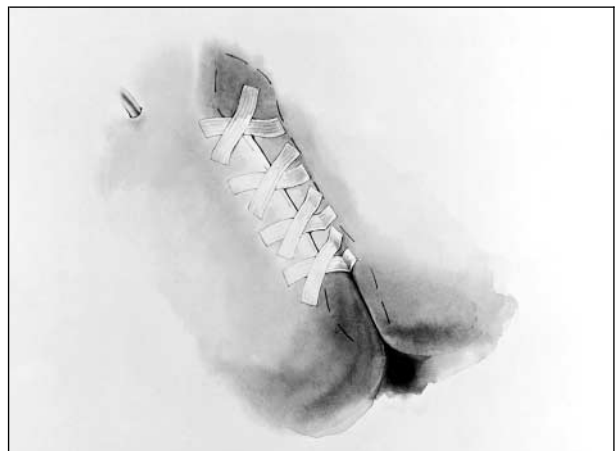
**Figure 1.** Cleft lift procedure. The buttocks are pushed together before surgery and the outer line of contact is marked.



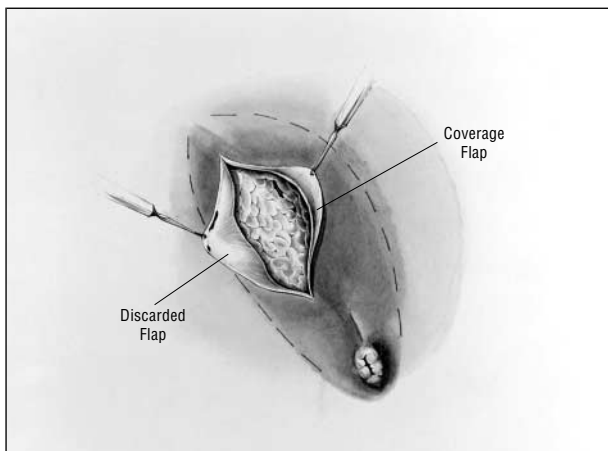
**Figure 4.** Fit of the flap from the right is checked before the flap from the left is cut away. Marking is designed for a cleft floor that is shallower and less tense and for a suture line near the surface.



**Figure 2.** The ellipse of skin to be removed is marked in red. The area to be mobilized as a full-thickness skin flap is outlined in blue.



**Figure 5.** Tape strips are applied in an X shape to control shearing forces. Subcuticular sutures are removed at 10 days.



**Figure 3.** Skin flaps 7 mm thick. Deep, scarred abscess walls may be left in place after scrubbing removes granulations from surfaces of cavities and tunnels. The left flap will be removed soon and the right will provide coverage.

nique, a videotape of the operation is available gratis from the authors.)

Secretions can be aspirated for 4 days with an optional suction drain. Anaerobic and aerobic bacteria are controlled with metronidazole, 250 mg, and cephalexin sodium, 1 gm, given

intravenously 30 minutes before surgery, and metronidazole, 250 mg, and cephalexin hydrochloride, 250 mg, given 4 times a day by mouth for 4 days after surgery. Ambulation and sitting begin immediately; hospitalization is less than 24 hours even in severe cases. Patients with small problems are treated as outpatients. Hematomas, which are rare, are scrubbed out and reclosed. Patients apply povidone-iodine 4 times a day for 3 days and wash wounds with soap and water from the second day.

## RESULTS

### CURRENT SURGERY

Twenty-eight of the 31 patients underwent the cleft lift procedure. This procedure was not used in 3 patients because examination showed that previous wide excisions had resulted in significant wound tension with recurrent painful stretching or even skin tears. In these cases, we used a small Z- or Y-V-plasty placed out on each buttock and away from the midline to release tense skin; in all 3 cases, this solved the problem.

Patients were contacted for follow-up by office visits, mail, or telephone. We were able to contact 27 patients (87%), with a median postrepair follow-up of 20

months (range, 1 month to 15 years). (We are using the median rather than the average to represent pooled data because several patients are outliers; using an average would distort the impression of the number of years of follow-up.)

Wounds in all 31 patients healed, 22 immediately, with sutures removed 1 week after a single operation. Six more patients' wounds healed after the single operation but slightly more slowly, as the residual open segments of their wounds closed secondarily. Three patients required later small operative revisions as adjustments of the original repair, and all 3 healed. The longest interval to cure was 13 months in 1 obese patient, who experienced minimal discomfort while minor outpatient revisions and local care completed healing of the cleft lift. Including this outlier, cumulative healing time for all 31 patients was 17 months. Of the 27 patients we were able to contact at follow-up, all remained healed.

### PREVIOUS SURGERIES

The most common failed previous operation, used 73 times, was wide excision of affected tissue that was followed by suture closure (38 operations), wound packing (24 operations) (as diligently as weekly for a year in 1 patient), muscle or buttock rotation (6 operations), and Z-plasty (5 operations). The other procedure used, incision and drainage, was applied 68 times. Incision and drainage effectively relieved the pain of acute abscesses, but it unfortunately failed to address the source of recurrent disease. In another patient, a massive rotation of both buttocks left a deep cleft in the midline and healing failed. These 31 patients who had refractory pilonidal disease and persistently open wounds had undergone an average of 5 operations before referral (range, 2-13 operations; total for group, 141 operations).

Why these operations failed appears in the **Table**. In 16 patients, a surgical repair left a sutured or packed incision at the bottom of a deep and dirty cleft. In 7 cases, an overhang left by a contracting scar from previous repair resulted in a tight, airless pocket. At the bottom of this pocket, the previously normal epidermis broke down under the adverse conditions. In 5 patients, the cause of failure was retention of the midline pore that initiates most original pilonidal abscesses<sup>2</sup>; without appropriate removal of this nidus of pilonidal disease, abscesses reform, often repeatedly. One of those 5 patients had received 9 incisions for acute abscess without addressing the source. That pore as a source can be difficult to identify because it is hidden in the edema of acute abscess but becomes obvious when edema has cleared 1 week after drainage. In the presence of a recurrent abscess, an insignificant-looking pore in the midline distal to the abscess should be sought as the cause. Finally, failure in 3 cases was due to wound tension that tore skin or stretched it painfully when the patient sat. Excessive skin removal at previous surgery created this problem.

Particularly striking was the protracted course of these conditions. Despite previous wide excision surgery, which was often aggressive, these patients carried disease for years. The 31 patients had accumulated a me-

### Why Operations Failed in 31 Patients

Cause of Failure	No. of Subjects	Treatment That Healed Wound
Deep and airless cleft	16	Cleft lift
Overhanging scar from previous surgery	7	Cleft lift, distal, to smooth cleft floor
Original pore of origin not treated	5	Cleft lift, limited, to remove pore
Too much skin removed at previous surgery	3	Bilateral Z- or Y-V-plasty to release tension

dian of 6 years of open wounds (range, 1-37 years; group total, 252 years). Five patients had endured 20 to 37 years of open wounds; clearly, observation alone does not solve these problems.

### COMMENT

To our knowledge, this is the first study to identify the reasons for nonhealing in extreme cases of refractory pilonidal disease. We treated these difficult cases with the cleft lift procedure. The success of this procedure strongly supports a new paradigm in pilonidal disease, whereby epidermal damage and repair are the key elements in pathologic features and cure.

Deep abscesses and fistulas characterize advanced pilonidal disease. However, the likely sources of both initial disease and nonhealing pilonidal wounds are superficial and subtle; one must direct one's attention away from the obvious and profound changes that occur secondarily. Instead, to achieve healing, attention must be focused on the adverse local conditions that damage the epidermis. Study of these 31 cases showed that healing fails at the bottom of deep, moist, and warm clefts despite carefully placed packing or stitches. Even normal skin breaks down in such sites.

Many current instructions for pilonidal care<sup>13-17</sup> call for wide excision of all granulating wounds, abscesses, tunnels, and fistulas, often to the periosteum. However, the wide excision follows an old paradigm that holds that defective and inflamed deep tissues are the source of nonhealing in pilonidal disease. Our findings suggest that deep tissue damage, although obvious, is not the primary source of nonhealing, but rather is a secondary effect. The source of nonhealing cannot be deficiencies of deep tissue competence or of deep tissue oxygenation from capillaries: neither of these was changed by our efforts, yet the patients recovered.

Thus, the primary source of surgical failures is not weak deep midline tissues but rather the shape of the gluteal cleft (or of a postsurgical structure such as the overhang), which creates the moist, warm, bacteria-friendly environment. As this and similar previous studies have shown, when midline "defective" skin is transferred toward convex surfaces, it heals normally.

This new paradigm of epidermal origin of pilonidal disease has important implications for initial management of the disease. Our experience with nearly 600 other patients has taught us that simpler techniques such as shaving, pit removal, and lateral drainage can usually avoid unhealed wounds.<sup>2,18,19</sup> Armstrong and Barcia,<sup>8</sup> Rick-



les,<sup>9</sup> and Lord and Millar<sup>10</sup> all left deep tissues in place, with similar success. In addition to results presented here, the work of these researchers further erodes support for wide excision of deep tissues as treatment for nonhealing.

The operation described in this article simplifies the technique used by its originators, Karydakias<sup>6</sup> and Kitchen.<sup>7</sup> We avoid their step of removal of all deep inflamed tissue and use of thick flaps of fat attached to skin, since we shift skin alone. We have termed this modified procedure *cleft lift* since it reduces the depth of the cleft. It relocates the healing line, moving it out to the surface. Muscle and fascia are never divided or shifted. Some skin is removed, but it is only to reshape the cleft to restore favorable wound healing conditions. The wall of the pilonidal abscess cavity is often left in place, since it is normal fibrous tissue and will heal.

This report collected the most severe complications of pilonidal care in our experience. Most of these complications can be prevented by improved early care. Shaving, pulling hairs from the pores, and careful cleaning may be enough for earliest disease. Incision alone controls limited disease when the incision passes through the pit and is followed by curettage or brushing out. These and other simple methods, often in the office, have been described.<sup>8-10,20,21</sup> We advocate use of the cleft lift if simpler treatments fail and for larger primary disease with multiple pits in a deep and tight cleft, as well as for the complex unhealed wounds described in this study.

## CONCLUSIONS

The most common cause of persistent open wounds after surgery for pilonidal disease is the deep cleft and the moist, bacteria-laden, anaerobic conditions there that arrest healing. The mystery of unhealed pilonidal disease is solved by understanding that the shape of the cleft and the conditions generated within that cleft inhibit epidermal closure and are the reason for the failure to heal. A simple operation solves these problems. It moves a skin flap across the cleft after mobilization from the cleft wall. This reduces cleft depth and brings the suture line off the midline onto a convex surface exposed to conditions that promote healing.

Corresponding author and reprints: Thomas Bascom, MD, 1200 Hilyard St, Suite 450, Eugene, OR 97401 (e-mail: thomasbascom@yahoo.com).

## REFERENCES

1. Kingsnorth AN. Invited comment on pilonidal disease. *Curr Pract Surg*. 1994;6:181.
2. Bascom JU. Pilonidal disease: origin from follicles of hairs and results of follicle removal as treatment. *Surgery*. 1980;87:567-572.
3. Marks J, Harding KG, Hughes LE. Staphylococcal infection of open granulating wounds. *Br J Surg*. 1987;74:95-97.
4. Hunt TK, Conolly WB, Aronson SB, Goldstein P. Anaerobic metabolism and wound healing: a hypothesis for the initiation and cessation of collagen synthesis in wounds. *Am J Surg*. 1978;135:328-332.
5. Allen DB, Maguire JJ, Mahdavi M, et al. Wound hypoxia and acidosis limit neutrophil bacterial killing mechanisms. *Arch Surg*. 1997;132:991-996.
6. Karydakias GE. New approach to the problem of pilonidal sinus. *Lancet*. 1973;2:1414-1415.
7. Kitchen PRB. Pilonidal sinus: experience with the Karydakias flap. *Br J Surg*. 1996;83:1452-1455.
8. Armstrong JH, Barcia PJ. Pilonidal sinus disease: the conservative approach. *Arch Surg*. 1994;129:914-919.
9. Rickles J. Ambulatory surgical management of pilonidal sinus. *Am Surg*. 1974;40:237-240.
10. Lord PH, Millar DM. Pilonidal sinus: a simple treatment. *Br J Surg*. 1965;52:298-300.
11. Karydakias GE. Easy and successful treatment of pilonidal sinus after explanation of its causative process. *Aust N Z J Surg*. 1992;62:385-389.
12. Brearley R. Pilonidal sinus: a new theory of origin. *Br J Surg*. 1969;13:62-67.
13. Quinodoz PD, Chilcott M, Grolleau JL, Chavoin JP, Costagliola M. Surgical treatment of sacrococcygeal pilonidal sinus disease by excision and skin flaps: the Toulouse experience. *Eur J Surg*. 1999;165:1061-1065.
14. Erdem E, Sungurtekin U, Nessar M. Are postoperative drains necessary with the Limberg flap for treatment of pilonidal sinus? *Dis Colon Rectum*. 1998;41:1427-1431.
15. Cruz AB, Aust JB. Lesions of the skin and subcutaneous tissue. In: Hardy JD, ed. *Hardy's Textbook of Surgery*. Philadelphia, Pa: JB Lippincott Co; 1988:320-338.
16. Keighley MRB. Anorectal disorders. In: Baker R, Fischer JE, eds. *Mastery of Surgery*. Vol 2. Philadelphia, Pa: Lippincott Williams & Wilkins; 2001:1638-1656.
17. Rosen W, Davidson JSD. Gluteus maximus musculocutaneous flap for the treatment of recalcitrant pilonidal disease. *Ann Plast Surg*. 1996;37:293-297.
18. Bascom JU. Repeat pilonidal operations. *Am J Surg*. 1987;154:118-122.
19. Bascom JU. Pilonidal sinus. *Curr Pract Surg*. 1994;6:175-180.
20. da Silva JH. Pilonidal cyst: cause and treatment. *Dis Colon Rectum*. 2000;43:1146-1156.
21. Bascom JU. Pilonidal disease: long-term results of follicle removal. *Dis Colon Rectum*. 1983;26:800-807.